

Neuropsychological Findings in Congenital and Acquired Childhood Hydrocephalus

Maria Mataró,¹ Carme Junqué,^{1,3} Maria Antonia Poca,² and Juan Sahuquillo²

Hydrocephalus is an increase in cerebrospinal fluid volume that can be caused by a variety of etiologies. The most common congenital and acquired causes of hydrocephalus are spina bifida, aqueduct stenosis, and preterm low birthweight infants with ventricular hemorrhage. In general, the literature suggests mild neuropsychological deficits associated with hydrocephalus, which are predominant in visuospatial and motor functions, and other nonlanguage skills. Although the precise nature of the neuropsychological deficits in hydrocephalus are not completely known, several factors such as etiology, raised intracranial pressure, ventricular size, and changes in gray and white matter tissue composition as well as shunt treatment complications have been shown to influence cognition. In fact, the presence of complications and other brain abnormalities in addition to hydrocephalus such as infections, trauma, intraventricular hemorrhage, low birthweight, and asphyxia are important determinants of the ultimate cognitive status, placing the child at a high risk of cognitive impairment.

KEY WORDS: hydrocephalus; infant; childhood; neuropsychological.

Hydrocephalus is an increase in cerebrospinal fluid (CSF) volume that can be caused by a variety of etiologies. It is accompanied by enlargement of the ventricles, and of the head itself if the cranial sutures are still open. Hydrocephalus is produced by an obstruction to CSF flow at any point along its path, by impaired absorption or, more rarely, by an excess of CSF production (Del Bigio, 1993). It has traditionally been classified as congenital or acquired, communicating or noncommunicating, and complicated with other brain disturbances or uncomplicated (Fletcher *et al.*, 1995; see Table I).

NATURAL HISTORY OF UNTREATED HYDROCEPHALUS AND ITS TREATMENT

Before the introduction of valve shunting systems mortality was very high, varying from 45 to 53% in dif-

ferent series (Hirsch, 1992). The majority of children who survived probably presented a type of hydrocephalus of slow evolution or a spontaneous arrest; only 38% of survivors achieved normal intellect (Laurence, 1958; Laurence and Coates, 1962). Overall, in the preshunt era, about 50% of children died, 17% were dependent, 13% were independent but unable to work during their adult life, and 20% were able to work (Hirsch, 1992).

With the advent of shunting procedures in the second half of the twentieth century, the treatment of hydrocephalus became more efficient: Mortality fell to around 15%, and morbidity also decreased considerably. About 27% of the patients are fully dependent, 16% independent although unable to work, and about 42% normal and able to work. Intelligence scores have also improved, although they are still far from normal. Twenty-eight percent of the Intelligence Quotients (IQs) are under 60, 21% between 60 and 80, and 52% above 80. Only 46% of children eventually attend a normal school (Hirsch, 1992).

At present the only effective treatment for most patients with hydrocephalus is the CSF shunt. This procedure consists of deviating the CSF from the ventricle to another body space, usually the peritoneal cavity or atrium, using a mechanical tube and valve system. Treatment is

¹Department of Psychiatry and Clinical Psychobiology, Faculty of Psychology, University of Barcelona, Barcelona, Spain.

²Service of Neurosurgery, Vall d'Hebron University Hospitals, Barcelona, Spain.

³To whom correspondence should be addressed at Dpt. de Psiquiatria i Psicobiologia Clínica, Facultat de Psicologia, Universitat de Barcelona, Passeig de la Vall d'Hebron 171, 08035 Barcelona, Spain; e-mail: cjunque@psi.ub.es.

Table I. Classifications of Hydrocephalus

<i>Etiology</i>
Congenital
Aqueduct stenosis
Dandy-Walker syndrome
Chiari malformation
Vein of Galen aneurism
Postnatal or acquired
Acquired aqueduct stenosis
Supratentorial masses causing tentorial herniation
Intraventricular haematoma
Tumours (ventricular, pineal region, posterior fossa)
Abscesses/granuloma
Arachnoid cysts
<i>Site of outflow obstruction</i>
Noncommunicating or obstructive
Obstruction of CSF flow within the ventricular system
Communicating
Obstruction of CSF flow outside the ventricular system. There is interference with reabsorption or an overproduction of CSF while pathways within the ventricular system remain functional
<i>Presence of complications</i>
Complicated hydrocephalus
Hydrocephalus associated with other clinical problems
Uncomplicated hydrocephalus
Only hydrocephalus

undertaken on the assumption that draining CSF prevents further damage to the brain, reverses part of the injury already inflicted, and improves brain function (Del Bigio, 1993). In experimental and clinical studies, shunting has been shown to reduce intracranial pressure, decrease ventricular size, grossly reconstitute the distorted anatomy, and improve neurochemical and cognitive functioning (Da Silva *et al.*, 1994; Del Bigio *et al.*, 1997; Hanlo *et al.*, 1997; Kriebel *et al.*, 1993; McAllister II *et al.*, 1991; Nakada *et al.*, 1992; Suda *et al.*, 1994; Tashiro and Drake, 1998). In experimental studies, Suda *et al.* (1994) and Del Bigio *et al.* (1997) demonstrated that early shunting in hydrocephalic rats prevented learning disability, whereas late shunting was associated with gradual, but incomplete, recovery (Del Bigio *et al.*, 1997). Unfortunately, the shunt technique may have significant (and numerous) postoperative complications. The rate of postoperative infection varies according to author, ranging usually from 5 to 20%. The rate of shunt failures because of other causes is also substantial and time-related. A per-patient shunt revision of 1.5–2.9 has been reported (Kokkonen *et al.*, 1994; McCullough and Balzer-Martin, 1982; Rosseau *et al.*, 1992). Since the successful development of shunt procedure in the 1970s, the various complications of the treatment has been gradually refined. Prognosis of children born with hydrocephalus is now more favorable, as reflected by a declining mor-

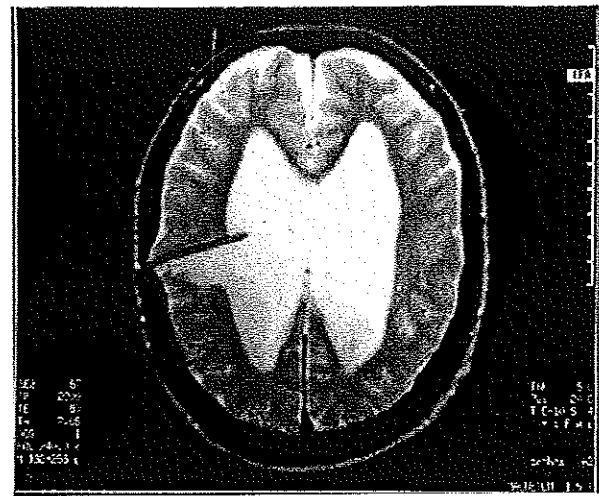


Fig. 1. Axial T2 MR (Magnetic Resonance) scan of a patient with congenital hydrocephalus shunted in infancy. Note the shunt valvula inserted in the right lateral ventricle.

tal and morbidity during the last two decades due to surgical advances (McCullough and Balzer-Martin, 1982; Fig. 1).

THE IMPACT OF HYDROCEPHALUS ON THE BRAIN

The impact of an enlarged ventricular system on the developing brain is complex. Hydrocephalus produces increased intraventricular pressure that causes expansion of the ventricles and displacement of adjacent brain structures. The structural and functional alterations appear to occur due to the mechanical distortion of the brain, combined with impaired cerebral blood flow and changes in metabolism and neurotransmission (Braun *et al.*, 1997; Caner *et al.*, 1993; Catalan *et al.*, 1994; Da Silva *et al.*, 1994; Del Bigio, 1993; Nakada *et al.*, 1992; Tashiro *et al.*, 1997; Tashiro and Drake, 1998). In both human and experimental animal hydrocephalus several brain structures have been found to suffer damage: the ependyma may sustain focal destruction; the cerebral blood vessels may be distorted and collapse; the corpus callosum stretched, thinned, and displaced upward; other white matter tracts, especially the axons and myelin in the periventricular white matter, are normally affected; the caudate nucleus compressed, and the cortical neurons may also suffer injury (Del Bigio, 1993). Table II shows the MRI findings that can be found in hydrocephalus.

The nature and distribution of the neuropathological changes depend on the age at which hydrocephalus develops, the rate and magnitude of ventricular dilatation, and

Table II. Common MRI Findings in Hydrocephalus (El Gammal *et al.*, 1987)

1. Dilatation of the third ventricle
2. Inferior bowing and displacement of the hypothalamus
3. Depression of the posterior fornix with increase in the superior inferior dimensions of the lateral ventricles
4. Uniform smooth thinning and elevation of the corpus callosum
5. Intraventricular flow void due to CSF movement
6. Paraventricular high signal on proton density and on T2 weighted images

the duration. In the infant, prior to suture fusion, massive ventricular enlargement and head expansion may occur. With obstruction, the ventricles expand in a posterior-to-anterior direction (Del Bigio, 1993). Severe hydrocephalus leads to compression of the cerebral cortex, with reduction of the overall brain mass and the cortical mantle, particularly in the parietal and occipital regions (Dennis *et al.*, 1981; Fletcher *et al.*, 1996b; McAllister II *et al.*, 1991). In older children and adults, ventricular dilatation is usually not so extensive as in infants.

As shunt surgery can only incompletely reverse the damage and the potential for reversal lessens as the duration of the hydrocephalus increases (particularly in neonates) the timing of CSF shunt procedures is a concern. Neurosurgeons are constantly weighing the known complications of shunt placement against the risks of delayed treatment (Tashiro and Drake, 1998). Appropriate indications and timing for the insertion of a CSF shunt are as yet not known. Many children with ventriculomegalia will experience spontaneous arrested hydrocephalus which is nonetheless not free from cognitive and developmental disturbances (Liechty *et al.*, 1983b).

In older patients with childhood hydrocephalus, both those not previously operated and those with nonfunctioning shunts, moderate and severe ventriculomegalia is often found in the absence of clinical signs of raised intracranial pressure. Some authors have indicated that although the hydrocephalus is apparently arrested, the disorder may in fact have a detrimental effect on cerebral function in certain patients (Bret and Chazal, 1995; Di Rocco *et al.*, 1977; Hammock *et al.*, 1976; Kirkpatrick *et al.*, 1989; Larsson *et al.*, 1999; Mataro *et al.*, 2000; McLone and Partington, 1993; Torkelson *et al.*, 1985; Whittle *et al.*, 1985). We studied 23 young adults with spina bifida and assumed arrested hydrocephalus, previously shunted or not, who had no overt signs of increased intracranial pressure despite the presence of an active or compensated hydrocephalus according to intracranial pressure monitoring criteria. Shunt surgery in this patient group improved their neuropsychological functioning. Six months after surgery, significant improvements were found in ver-

bal and visual memory, motor coordination, and attention and cognitive flexibility (Mataro *et al.*, 2000). Because of the fact that prognosis for the treatment of hydrocephalus has improved enormously, recent studies argue for an active approach in the management of these patients with an apparent arrested hydrocephalus. Because shunt surgery can improve their cognitive functioning, all patients with ventriculomegalia deemed to have arrested hydrocephalus should be carefully monitored (Mataro *et al.*, 2000).

MOST COMMON CONGENITAL AND ACQUIRED CHILDHOOD HYDROCEPHALUS

Hydrocephalus may be caused by a variety of etiologies. Congenital causes of hydrocephalus are for example spina bifida and associated Chiari malformation, aqueduct stenosis, and Dandy-Walker syndrome. Other common etiologies of acquired infant and childhood hydrocephalus include premature infants with intraventricular haemorrhage, meningitis, traumatic brain injury, tumor, and infectious diseases. The origin of hydrocephalus is an important factor when it comes to outcome. Congenital causes of hydrocephalus may be associated to other abnormalities of neuroembryogenesis such as partial or complete agenesis of corpus callosum, interdigitation of the hemispheres, or a small posterior fossa. In acquired hydrocephalus, the previously sustained damage is also a major determinant of the long-term developmental outcome of these children. It is therefore essential to analyze the type and degree of pathological condition behind hydrocephalus.

Early onset hydrocephalus, both congenital and acquired, is often associated with abnormalities of the corpus callosum. Because of the anterior-posterior sequence of the callosal development, depending on the timing of the insult there may be absence of all or only portions of the corpus callosum. When there is partial agenesis from congenital disorders, the genu is nearly always present because it begins to develop before the body. The rostrum and the splenium are most likely to be small or absent. In secondary hydrocephalus, such as intraventricular haemorrhage in premature children, the rostrum and splenium are most commonly present, and the genu and body thinned or absent (Barkovich, 1995). Correlational studies of the size of the corpus callosum and cognitive and motor functions provided evidence of its role played in nonverbal and motor skills (Fletcher *et al.*, 1992a, 1996a). Recent studies suggest that children with partial agenesis of the corpus callosum, when the splenium is missing and the body hypoplastic, seem to have more difficulty transferring patterned visual information from one hemisphere

to another. Tactile and auditory transfer of information are essentially similar to normals (Hannay, 2000).

Spina Bifida

Spina bifida results from a failure of the neural tube to close completely. The defect may consist in incomplete fusion of the vertebral branches (spina bifida occulta) or may also involve a protrusion of the meninges (meningocele) or the meninges and neural structures (myelomeningocele). Myelomeningocele is the most frequent congenital cause of hydrocephalus in children. About 95% of the children with myelomeningocele have an associated Chiari II malformation that introduces a barrier to CSF outflow from the ventricular system to the subarachnoid space. Spina bifida is also associated with corpus callosum defects and other less obvious abnormalities of the brain such as interdigitation of the hemispheres, a small posterior fossa, and other hindbrain anomalies. Children with spina bifida sustain a variety of sensory and motor deficits, the severity of which depends on the spinal level and the degree of cord involvement of the dysraphic lesion. Impaired motor skills and hand function may also result from the Chiari malformation, which produces major effects on cerebellar functioning. They may also suffer disturbance of oculomotor function (Dennis *et al.*, 1981).

Spina bifida and hydrocephalus is associated with mild cognitive impairment, poor academic skills in arithmetic, disturbances in visual and tactile perception, fine motor speed, and perceptual motor-integration, and mildly limited ability to reason and judge cause and effect adequately (Hurley *et al.*, 1990; Prigatano *et al.*, 1983; Thomson *et al.*, 1991). IQ scores tend to be in the average, low-average and borderline range (Chervenak *et al.*, 1984; Hurley *et al.*, 1990; Ito *et al.*, 1997; McCulloch and Balzer-Martin, 1982; McLone *et al.*, 1982). Several studies have shown specific biological and medical risk factors in this population. The presence of complications (McLone *et al.*, 1982), and the lesion level and shunt status has been shown to have significant effects on IQ (Blaymore *et al.*, 1997; Fig. 2).

Aqueduct Stenosis

Children with aqueduct stenosis present ventriculomegalia due to blockage of the normal CSF flow at the aqueduct of Sylvius. Aqueduct stenosis is often accompanied by abnormalities of the corpus callosum, including partial agenesis. Dennis *et al.* (1981) found that children with aqueduct stenosis had lower levels of nonverbal intelligence, in relation to their own verbal cognitive skills, than

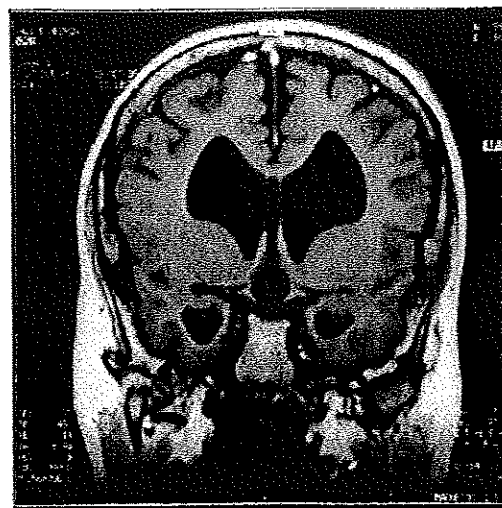


Fig. 2. Coronal T1 MR image of a 23-year-old girl with spina bifida myelomeningocele and hydrocephalus shunted 19 days after birth. It demonstrates expansion of the lateral ventricles and third ventricle. She showed an average level on verbal learning, impaired long-term retrieval and marked deficits in visual memory tasks. Notable deficits were also found in visual spatial processing and motor functioning.

that of postnatal etiologies. McCulloch and Balzer-Martin (1982) found that in children with aqueductal block mean IQ fell into the borderline category. In a recent long-term follow-up of 78 patients with aqueductal stenosis, 68% of the cases achieved a good outcome. Although some of them presented motor abnormalities, all of these patients could attend normal school courses or have regular jobs. Twenty-four percent of the cases were moderately disabled, and 8% severely handicapped and totally dependent. Unfortunately, only 45% of the patients showed a normal cognitive and motor development (Villani *et al.*, 1995).

Hydrocephalus in Preterm Low Birthweight Infants and Ventricular Haemorrhage

Intraventricular hemorrhage as a consequence of prematurity and low birthweight is the most common perinatal etiology of hydrocephalus. Most investigators have found an incidence of hemorrhage of 40% in infants of very low birthweight (<1,500 g), with subsequent posthemorrhagic ventricular dilatation in a significant percentage of cases (Lietchy *et al.*, 1983a). Hydrocephalus in these infants is characteristically associated with a moderate to severe hemorrhage. The hemorrhage leads to destruction of the brain and may result in the development of a porencephalic cyst with concomitant neurologic deficits. Specific neurological deficits may depend upon the laterality

and severity of the hemorrhages and the resulting porencephalic cyst. Both the hemorrhage and hydrocephalus can cause corpus callosum anomalies. These infants are at high risk of acute medical complications: hypoxia, respiratory problems, seizure activity, and feeding difficulties that further compromise the infants' development. Many studies have indicated that infants who sustain severe hemorrhages have a worse outcome than infants with lesser bleeds do (Dykes *et al.*, 1989; Hanigan *et al.*, 1991; Levy *et al.*, 1997; Pikus *et al.*, 1997). Birthweight and gestational age has also been associated with neurobehavioral development (Dykes *et al.*, 1989; Fletcher *et al.*, 1997; Levy *et al.*, 1997). The poor outcome of these children has been related to previously sustained brain damage in addition to the hydrocephalus (Liechty *et al.*, 1983a).

NEUROPSYCHOLOGICAL CONSEQUENCES OF INFANT AND CHILDHOOD HYDROCEPHALUS

Hydrocephalus is associated with a variety of cognitive deficits. Although several reports suggest a normal or low-average intelligence in hydrocephalic children, this does not necessarily mean the absence of neuropsychological deficits (Berker *et al.*, 1992; Prigatano *et al.*, 1983). Persistent difficulties in academic performance in hydrocephalic children are often found, even with properly operating shunts. This poor academic performance may be associated with neuropsychological deficits not sampled by traditional IQ measures (Prigatano *et al.*, 1983). Many previous studies of infant and childhood hydrocephalus have focused on intelligence measures; few investigations have reported on comprehensive neuropsychological assessments. In general, the literature suggests mild neuropsychological deficits associated with hydrocephalus, which are predominant in visuospatial and motor functions, and other nonlanguage skills. Verbal skills are intact in many children, although problems with language at the level of discourse are reported. It has been suggested that the nature of the deficits in hydrocephalus is consistent with the neurobehavioral characteristics of the Nonverbal Learning Disabilities (NLD) Syndrome (Fletcher *et al.*, 1995).

Intelligence

Congenital or acquired hydrocephalus in childhood may affect the level and pattern of intelligence. Overall IQ has been reported to be in the range of low-average or below (McCullough and Balzer-Martin, 1982; McLone *et al.*, 1982). The most frequent finding is that nonver-

bal intelligence is less developed than verbal intelligence (Dennis *et al.*, 1981; Donders *et al.*, 1991; Fletcher *et al.*, 1992b). The level of intelligence has been related to the presence and type of hydrocephalus (Dennis *et al.*, 1981; McCullough and Balzer-Martin, 1982), the ventricular size or thickness of the cortical mantle before or after shunting (Liechty *et al.*, 1983b; McCullough and Balzer-Martin, 1982; Thompson *et al.*, 1982), shunt treatment (Fletcher *et al.*, 1997), the degree of myelination (Hanlo *et al.*, 1997; Van der Knaap *et al.*, 1991), raised intracranial pressure (Van der Knaap *et al.*, 1991), and the presence of complications (Dennis *et al.*, 1981; McLone *et al.*, 1982; Thompson *et al.*, 1982). In fact, the presence of complications and other brain insults in addition to hydrocephalus such as infections, trauma, intraventricular hemorrhage, low birthweight, and asphyxia are important determinants of the ultimate cognitive status, placing the child at a high risk of cognitive impairment. However, variables such as the number of shunt revisions have not been shown to have a significant effect on ultimately intellectual performance (Dennis *et al.*, 1981; Villani *et al.*, 1995). Conversely, in a long-term follow-up of children with hydrocephalus, moderately and severely disabled patients had lower shunt revisions and longer time interval between shunting and revisions than patients with more favorable prognosis (Villani *et al.*, 1995; Fig. 3).

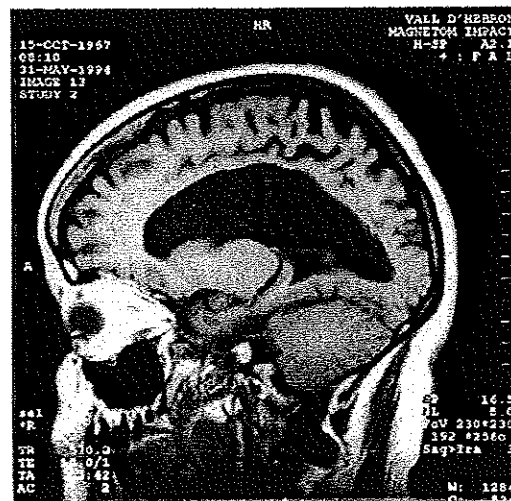


Fig. 3. Sagittal view of a congenital nonshunted hydrocephalus in a 27-year-old girl. Note the lateral ventricles enlargement and white matter degeneration. At present her intellectual scores place her in the low average range (Full Scale IQ = 84; Verbal IQ = 81; Performance IQ = 84). Memory scores reveal mild impairment in verbal memory and marked impairment in recall of nonverbal visual material. Lowered performance was also noted in visual perceptual skills and fine motor speed.

Visuospatial and Motor Skills

A reduced efficiency of complex visuospatial abilities in hydrocephalic children has been consistently documented (Donders *et al.*, 1991; Fletcher *et al.*, 1992b; Fletcher *et al.*, 1996b; Prigatano *et al.*, 1983). It has been suggested that the relative inefficiency of hydrocephalic children in these visuospatial measures is a reflection of dysfunction in the posterior regions of the brain (Dennis *et al.*, 1981; Donders *et al.*, 1991; Fletcher *et al.*, 1992a; Fletcher *et al.*, 1996b). Some studies have tried to relate these poorer nonverbal cognitive skills to the condition of the hydrocephalic brain and related factors. Dennis *et al.* (1981) found that in hydrocephalic children the presence of visual, motor or seizure symptoms, and posterior cortical-mantle thinning appears to be associated with poorer nonverbal intelligence. Fletcher *et al.* (1992a) and Fletcher *et al.* (1996a) have demonstrated a strong relationship between measures of spatial cognition and the area of corpus callosum and other white matter tracts. In another study, the same authors found that children with hydrocephalus and greater posterior cerebrospinal fluid percentages showed significantly poorer visuospatial skills. The more pronounced problems in these tests could be related to hydrocephalus-related changes in the posterior cortex that mediates visuospatial functions and to anomalies of the splenium of the corpus callosum that interconnects the primary and secondary visual cortex (Fletcher *et al.*, 1996b).

Poor performance on gross and fine motor function and bimanual motor function has also been reported. Hydrocephalus may impair gross motor function by deforming the cerebellum; affect fine motor control by disturbing the kinesthetic-proprioceptive basis of hand control; and impair bimanual motor function by causing stretching of the corpus callosum. These impairments in motor function, together with the visual abnormalities common in hydrocephalic children, may contribute to their difficulties in nonverbal tasks (Dennis *et al.*, 1981).

Memory

Systematic and comprehensive assessment of memory functioning in hydrocephalic children has not been carried out. The relationship between the type and pattern of memory deficits and hydrocephalus related factors have not been either established yet. The few studies performed regarding memory have offered mixed results. Some authors have found verbal and visual memory impairments (Fletcher *et al.*, 1992b; Prigatano *et al.*, 1983) whereas others have not (Donders *et al.*, 1991). Prigatano *et al.* (1983) found poorer initial verbal recall and poorer consistency of

recall over the five trials in the Fuld Object-Memory Test in a group of children shunted for uncomplicated hydrocephalus with normal IQ. They also found poorer performance in the Benton Visual Retention Test Graphomotor form, but not in the visual recognition form of the same test. Fletcher *et al.* (1992b) reported significant deficiencies on verbal and nonverbal selective reminding tests. In the study of Donders *et al.*, verbal memory was assessed by the Selective Reminding Test, and visual memory by the Spatial Memory subtest of the Kaufman Assessment Battery for Children. Although they did not report evidence of memory deficits in their sample, their patients showed a low performance in these tests and were not compared with a control group.

Language

Although differential right-hemisphere damage is frequently suggested by the well-documented finding of impaired visuospatial abilities and lower performance IQ, disturbances of language functioning, especially at the level of pragmatics and discourse, have also been reported in early hydrocephalus. Hydrocephalic language is neither globally impaired nor globally proficient. Rather, within particular language domains, hydrocephalics seem to be less-skilled (Dennis *et al.*, 1987).

Some patients with hydrocephalus manifest the "cocktail party syndrome," which is characterized by an hypervolubility behavior with good articulation, vocabulary above the apparent mental level, shallow intellect, and poor social and academic skills. The use of tangential language irrelevant to the conversation, excessive stereotypic phrases, overfamiliarity of manner, and verbal perseveration are also characteristics of this syndrome, all of which is reminiscent of a frontal lobe personality (Hurley *et al.*, 1990).

Tew and Laurence (in Hurley *et al.*, 1990) developed an operational definition of the "cocktail party syndrome" based on subjects meeting four out of five criteria (Table III). The "cocktail party syndrome" is particularly prevalent in individuals with spina bifida and hydrocephalus and has been reported to occur in 28–41% of hydrocephalic children. Factors such as intelligence level,

Table III. Criteria for Cocktail Party Syndrome

Fluent and well-articulated speech
Excessive use of social phrases
Overfamiliarity of manner
Verbal perseveration
Irrelevant verbosity

Note. Subject must meet four of five criteria.

sex, and the degree of physical handicap have also been implicated. The incidence appears to decrease with age.

Executive Functions

Measures involving nonverbal problem solving tasks, such as the Tower of London and the Wisconsin Card Sorting Test, have been reported deficient in children with shunted hydrocephalus (Fletcher *et al.*, 1995; Fletcher *et al.*, 1996a,b). Fletcher *et al.* (1995) found that patients solved significantly fewer correct problems in these tests. Because of the fact that there were no differences in the indices commonly associated with executive functions, the authors suggested that the findings could be interpreted in terms of problems with attention systems mediated by posterior regions of the brain. Morphometric studies have not been able to relate executive measures with hydrocephalus-related variations in brain tissue composition (Fletcher *et al.*, 1996a,b). These results seem to support the more pronounced posterior deficits associated to childhood hydrocephalus. As maturation of frontal lobe systems develops until adulthood, further studies of executive functioning in older hydrocephalic patients are required in order to clarify the effects of early hydrocephalus on frontal lobe functions.

Behavior

Data regarding the occurrence of behavioral problems in children with hydrocephalus is limited. In the preshunt era, Hagberg and Sjögren (1966) claimed that almost two thirds of children with hydrocephalus, with and without mental retardation, had significant behavioral problems. However, Fernell *et al.* (1991), in a sample of 81 children, 88% of whom were shunt treated, reported that only children with hydrocephalus and mental retardation had more behavioral problems than those with no retardation and controls. Children with hydrocephalus and without mental retardation did not differ from controls.

NEUROIMAGING STUDIES IN CHILDHOOD HYDROCEPHALUS

Some computerized tomography (CT) and magnetic resonance imaging (MRI) studies have been able to demonstrate and confirm the structural abnormalities in hydrocephalus and relate them with the cognitive status of the brain. These studies may help to elucidate the anatomical and physiopathological bases of hydrocephalus, and

increase the understanding of the relationship between brain structure and function.

The degree of hydrocephalus measured on CT scans has been related to IQ scores (Lietchy *et al.*, 1983b; McCullough and Balzer-Martin, 1982; Thompson *et al.*, 1982). MRI studies have found relationships between the extent of myelination and psychomotor development (Hanlo *et al.*, 1997; Van der Knaap *et al.*, 1991). Other hydrocephalus-related changes in the lateral ventricles, and white matter tracts (corpus callosum and internal capsules) were also related with cognitive skills, the correlations being higher for nonverbal measures (Fletcher *et al.*, 1992a, 1996a). Interestingly, the same authors (Fletcher, *et al.*, 1996) recently found a reduction in overall gray matter percentages and corresponding increases in CSF percentages that were more pronounced in posterior regions, whereas white matter percentages were reduced only in the left posterior quadrant. Correlations of posterior, but not anterior, CSF and gray matter percentages with verbal and nonverbal cognitive abilities were significant. The stronger correlations for posterior than anterior brain measurements may reflect the posterior-to-anterior progression of childhood hydrocephalus, corpus callosum anomalies, or both. These findings also demonstrate the significant contribution of gray matter destruction or dysfunction in the neuropsychological deficits found in hydrocephalus.

Little is known about cerebral blood flow and metabolism in children with hydrocephalus. In four hydrocephalic infants without severe neurological deficits, positron emission tomography (PET) scan showed hypoperfusion in frontal, parietal, and visual association cortices that surrounded dilated anterior or posterior horns of the lateral ventricles. Postshunting studies in two of the patients demonstrated increased cerebral metabolic rate of oxygen, although little change was observed in cerebral blood flow (Shirane *et al.*, 1992). In another study using single photon emission computed tomography technique (SPECT) two infants with posthemorrhagic hydrocephalus were assessed. Markedly diminished bilateral perfusion was seen in one infant with increased head circumference and bulging fontanelle, which recovered following shunt placement. The other infant had a mild ventriculomegaly and the SPECT revealed no abnormalities in cerebral perfusion (Haddad *et al.*, 1994).

CONCLUSION

The precise neuropsychological effects of hydrocephalus differ between individuals and are further complicated by other brain abnormalities, as well as by the

preexisting degrees of ability and personality. The child's prognosis is as much based on the hydrocephalus, as on its cause and treatment complications. It is not surprising therefore that although for instance some children are cognitively normal, others may have subtle neuropsychological deficits and others a severe mental retardation. Despite that, hydrocephalus by itself is associated with mild cognitive deficits in certain domains of function with relative preservation of others.

Recent advances in medical technology and aggressive treatment have increased the rates of survival and reduced morbidity. Many children with hydrocephalus now have the same life expectancy as the normal population. Nevertheless, the peculiar characteristics of hydrocephalus expose these children to acute and chronic medical problems. Although chronological changes of neurologic and cognitive manifestations are well-known in early periods of development, little is known about the prognosis of medical, neuropsychological, and psychosocial problems of these children in adult life. Care must be taken even in asymptomatic patients with nonshunted ventriculomegalia or nonfunctioning shunts and assumed arrested hydrocephalus. Intellectual quotient scores might not be sensitive enough to the hydrocephalic condition. Careful medical monitoring and a comprehensive baseline neuropsychological assessment and longitudinal evaluation might be essential to document the stability of the hydrocephalic condition, shunt integrity, normal cognitive development, and any changes in neurobehavioral functioning. These data may be highly sensitive to the physiological status of hydrocephalus and may contribute significantly to decisions about shunt functioning. Neuropsychological assessment is also essential in monitoring rehabilitation strategies, academic planning, and preparation for gainful employment (Baron and Goldberger, 1993).

Hydrocephalus is a highly heterogeneous illness associated to a variety of etiologies, brain anomalies and insults, and therapeutic factors. Neuropsychological literature in hydrocephalic children is still limited and has several deficiencies. There are selection biases, inclusion of hydrocephalic patients of different etiologies, small samples and frequently failure to document the severity and type of hydrocephalus, the contribution of other brain abnormalities, and other therapeutic variables such as the valve systems used. Further neuropsychological studies concerning the complex association of hydrocephalus and cognition are required. Increasing access to new functional and structural neuroimaging methodologies will probably provide new clues to the understanding of the pathophysiology of hydrocephalus and insight on the manner in which hydrocephalus affects cognition. Such research would be

helpful to improve the cognitive development of children with early hydrocephalus.

ACKNOWLEDGMENT

This article has been partially supported by Grants 99/0968 and 97/0923 from the Fondo de Investigación Sanitaria (FIS).

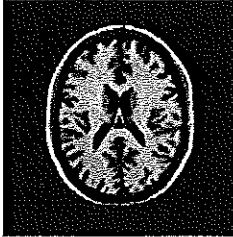
REFERENCES

- Barkovich, J. A. (1995). *Pediatric Neuroimaging* (2nd edn.). Raven Press, New York.
- Baron, I. D., and Goldberger, E. (1993). Neuropsychological disturbances of hydrocephalic children with implications for special education and rehabilitation. *Neuropsychological Rehabilitation* 3: 389-410.
- Berker, E., Goldstein, G., Lorber, J., Priestley, B., and Smith, A. (1992). Reciprocal neurological developments of twins discordant for hydrocephalus. *Developmental Medicine and Child Neurology* 34: 623-632.
- Blaymore Bier, J. A., Morales, Y., Liebling, J., Geddes, L., and Kim, E. (1997). Medical and social factors associated with cognitive outcome in individuals with myelomeningocele. *Developmental Medicine and Child Neurology* 39: 263-266.
- Braun, K. P., Dijkhuizen, R. M., de Graaf, R. A., Nicolay, K., Vandertop, W. P., Gooskens, R. H., and Tulleken, K. A. (1997). Cerebral ischemia and white matter edema in experimental hydrocephalus: A combined in vivo MRI and MRS study. *Brain Research* 757: 295-298.
- Bret, P., and Chazal, J. (1995). Chronic ("normal pressure") hydrocephalus in childhood and adolescence. A review of 16 cases and reappraisal of the syndrome. *Child's Nervous System* 11: 687-691.
- Caner, H., Atasever, A., Kilinc, K., Durgun, B., Peker, S., and Ozcan, O. B. (1993). Lipid peroxide level increase in experimental hydrocephalus. *Acta Neurochirurgica* 121: 68-71.
- Catalan, R., Sahuquillo, J., Poca, M. A., Molins, A., Castellanos, J. M., and Galar, R. (1994). Neuropeptide Y cerebrospinal fluid levels in patients with normal pressure hydrocephalus syndrome. *Biological Psychiatry* 36: 61-63.
- Chervenak, F. A., Duncan, C., Ment, L. R., Hobbins, J. C., McClure, M., Scott, D., and Berkowitz, R. L. (1984). Outcome of fetal ventriculomegaly. *Lancet* 2: 179-181.
- Da Silva, M. C., Drake, J. M., Lemaire, C., Cross, A., and Tuor, U. I. (1994). High-energy phosphate metabolism in a neonatal model of hydrocephalus before and after shunting. *Journal of Neurosurgery* 81: 544-553.
- Del Bigio, M. R. (1993). Neuropathological changes caused by hydrocephalus. *Acta Neuropathologica* 85: 573-585.
- Del Bigio, M. R., Crook, C. R., and Buist, R. (1997). Magnetic resonance imaging and behavioral analysis of immature rats with kaolin-induced hydrocephalus: Pre- and postshunting observations. *Experimental Neurology* 148: 256-264.
- Dennis, M., Fitz, C. R., Netley, C. T., Sugar, J., Harwood-Nash, D. C., Hendrick, E. B., Hoffman, H. J., and Humphreys, R. P. (1981). The intelligence of hydrocephalic children. *Archives of Neurology* 38: 607-615.
- Dennis, M., Hendrick, B., Hoffman, H. J., and Humphreys, R. P. (1987). Language of hydrocephalic children and adolescents. *Journal of Clinical and Experimental Neuropsychology* 9: 593-621.
- Di Rocco, C., Caldarelli, M., Maira, G., and Rossi, G. F. (1977). The study of cerebrospinal fluid dynamics in apparently "arrested" hydrocephalus in children. *Child's Brain* 3: 359-374.

- Donders, J., Rourke, B. P., and Canady, A. I. (1991). Neuropsychological functioning of hydrocephalic children. *Journal of Clinical and Experimental Neuropsychology* 13: 607-613.
- Dykes, F. D., Dunbar, B., Lazarra, A., and Ahmann, P. A. (1989). Post-hemorrhagic hydrocephalus in high-risk preterm infants: Natural history, management, and long-term outcome. *Journal of Pediatrics* 114: 611-618.
- El Gammal, T., Allen, M. B., Brooks, B. S., and Mark, E. K. (1986). MR evaluation of hydrocephalus. *American Journal of Neuroradiology* 149: 807-813.
- Fernell, E., Gillberg, C., and von Wendt, L. (1991). Behavioural problems in children with infantile hydrocephalus. *Developmental Medicine and Child Neurology* 33: 388-395.
- Fletcher, J. M., Bohan, T. P., Brandt, M. E., Brookshire, B. L., Beaver, S. R., Francis, D. J., Davidson, K. C., Thompson, N. M., and Miner, M. E. (1992a). Cerebral white matter and cognition in hydrocephalic children. *Archives of Neurology* 49: 818-824.
- Fletcher, J. M., Bohan, T. P., Brandt, M. E., Kramer, L. A., Brookshire, B. L., Thorstad, K., Davidson, K. C., Francis, D. J., McCauley, S. R., and Baumgartner, J. E. (1996a). Morphometric evaluation of the hydrocephalic brain: Relationships with cognitive development. *Child's Nervous System* 12: 192-199.
- Fletcher, J. M., Brookshire, B. L., Bohan, T. P., Brandt, M. E., and Davidson, K. C. (1995). Early hydrocephalus. In Rourke, B. P. (ed.), *Syndrome of Nonverbal Learning Disabilities. Neurodevelopmental Manifestations*, Guilford Press, New York, pp. 206-238.
- Fletcher, J. M., Francis, D. J., Thompson, N. M., Brookshire, B. L., Bohan, T. P., Landry, S. H., Davidson, K. C., and Miner, M. E. (1992b). Verbal and nonverbal skill discrepancies in hydrocephalic children. *Journal of Clinical and Experimental Neuropsychology* 14: 593-609.
- Fletcher, J. M., Landry, S. H., Bohan, T. P., Davidson, K. C., Brookshire, B. L., Lachar, D., Kramer, L. A., and Francis, D. J. (1997). Effects of intraventricular hemorrhage and hydrocephalus on the long-term neurobehavioral development of preterm very-low-birthweight infants. *Developmental Medicine and Child Neurology* 39: 596-606.
- Fletcher, J. M., McCauley, S. R., Brandt, M. E., Bohan, T. P., Kramer, L. A., Francis, D. J., Thorstad, K., and Brookshire, B. L. (1996b). Regional brain tissue composition in children with hydrocephalus. *Archives of Neurology* 53: 549-557.
- Haddad, J., Constantinesco, A., Brunot, B., and Messer, J. (1994). A study of cerebral perfusion using single photon emission computed tomography in neonates with brain lesions. *Acta Paediatrica* 83: 265-269.
- Hagberg, B., and Sjögren, I. (1966). The chronic brain syndrome of infantile hydrocephalus. *American Journal of Diseases of Children* 112: 189-196.
- Hammock, M. K., Milhorat, T. H., and Baron, I. S. (1976). Normal pressure hydrocephalus in patients with myelomeningocele. *Developmental Medicine and Child Neurology* 37(Suppl.): 55-68.
- Hanigan, W. C., Morgan, A. M., Anderson, R. J., Bradle, P., Cohen, H. S., Cusack, T. J., Thomas-McCauley, T., and Miller, T. C. (1991). Incidence and neurodevelopmental outcome of periventricular hemorrhage and hydrocephalus in a regional population of very low birth weight infants. *Neurosurgery* 29: 701-706.
- Hanio, P. W., Gooskens, R. J., van Schooneveld, M., Tulleken, C. A., van der Knaap, M. S., Faber, J. A., and Willemse, J. (1997). The effect of intracranial pressure on myelination and the relationship with neurodevelopment in infantile hydrocephalus. *Developmental Medicine and Child Neurology* 39: 286-291.
- Hannay, H. J. (2000). Functioning of the corpus callosum in children with early hydrocephalus. *Journal of the International Neuropsychological Society* 6: 351-361.
- Hirsch, J. F. (1992). Surgery of hydrocephalus: Past, present and future. *Acta Neurochirurgica* 116: 155-160.
- Hurley, A. D., Dorman, C., Laatsch, L., Bell, S., and D'Avignon, J. (1990). Cognitive functioning in patients with spina bifida, hydrocephalus, and the "cocktail party" syndrome. *Developmental Neuropsychology* 6: 151-172.
- Ito, J., Saijo, H., Araki, A., Tanaka, H., Tasaki, T., Cho, K., and Miyamoto, A. (1997). Neuroradiological assessment of visuoperceptual disturbance in children with spina bifida and hydrocephalus. *Developmental Medicine and Child Neurology* 39: 385-392.
- Kirkpatrick, M., Engleman, H., and Minns, R. A. (1989). Symptoms and signs of progressive hydrocephalus. *Archives of Disease in Childhood* 64: 124-128.
- Kokkonen, J., Serlo, W., Saukkonen, A.-L., and Juolasmaa, A. (1994). Long-term prognosis for children with shunted hydrocephalus. *Child's Nervous System* 10: 384-387.
- Kriebel, R. M., Shah, A. B., and McAllister, J. P., II. (1993). The microstructure of cortical neuropil before and after decompression in experimental infantile hydrocephalus. *Experimental Neurology* 119: 89-98.
- Larsson, A., Stephensen, H., and Wikkelsø, C. (1999). Adult patients with "asymptomatic" and "compensated" hydrocephalus benefit from surgery. *Acta Neurologica Scandinavica* 99: 81-90.
- Laurence, K. M. (1958). The natural history of hydrocephalus. *The Lancet* 2: 1152-1154.
- Laurence, K. M., and Coates, S. (1962). The natural history of hydrocephalus. Detailed analysis of 182 unoperated cases. *Archives of Disease in Childhood* 37: 345-362.
- Levy, M. L., Masri, L. S., and McComb, J. G. (1997). Outcome for preterm infants with germinal matrix hemorrhage and progressive hydrocephalus. *Neurosurgery* 41: 1111-1118.
- Liechty, E. A., Bull, M. J., Bryson, C. Q., Kalsbeck, J. B., Jansen, R. D., Lemons, J. A., and Schreiner, R. L. (1983a). Developmental outcome of very low birth weight infants requiring a ventriculoperitoneal shunt. *Child's Brain* 10: 340-349.
- Liechty, E. A., Gilmor, R. L., Bryson, C. Q., and Bull, M. J. (1983b). Outcome of high-risk neonates with ventriculomegaly. *Developmental Medicine and Child Neurology* 25: 162-168.
- Mataro, M., Poca, M. A., Sahuquillo, J., Cuxart, A., Iborra, J., De la Calzada, M. D., and Junque, C. (2000). Cognitive changes after cerebrospinal fluid shunting in young adults with spina bifida and assumed arrested hydrocephalus. *Journal of Neurology, Neurosurgery and Psychiatry* 68: 615-621.
- McAllister, J. P., II, Cohen, M. I., O'Mara, K. A., and Johnson, M. H. (1991). Progression of experimental infantile hydrocephalus and effects of ventriculoperitoneal shunts: An analysis correlating magnetic resonance imaging with gross morphology. *Neurosurgery* 29: 329-340.
- McCullough, D. C., and Balzer-Martin, L. A. (1982). Current prognosis in overt neonatal hydrocephalus. *Journal of Neurosurgery* 57: 378-383.
- McLone, D. G., Czyzewski, D., Raimondi, A. J., and Sommers, R. C. (1982). Central nervous system infections as a limiting factor in the intelligence of children with myelomeningocele. *Pediatrics* 70: 338-342.
- McLone, D. G., and Partington, M. D. (1993). Arrest and compensation of hydrocephalus. *Neurosurgery Clinics of North America* 4: 621-624.
- Nakada, J., Oka, N., Nagahori, T., Endo, S., and Takaku, A. (1992). Changes in the cerebral vascular bed in experimental hydrocephalus: An angio-architectural and histological study. *Acta Neurochirurgica* 114: 43-50.
- Pikus, H. J., Levy, M. L., Gans, W., Mendel, E., and McComb, J. G. (1997). Outcome, cost analysis, and long-term follow-up in preterm infants with massive grade IV germinal matrix hemorrhage and progressive hydrocephalus. *Neurosurgery* 40: 983-989.
- Prigatano, G. P., Zeiner, H. K., Pollay, M., and Kaplan, R. J. (1983). Neuropsychological functioning in children with shunted uncomplicated hydrocephalus. *Child's Brain* 10: 112-120.
- Rosseau, G. L., McCullough, D. C., and Joseph, A. L. (1992). Current prognosis in fetal ventriculomegaly. *Journal of Neurosurgery* 77: 551-555.

- Shirane, R., Sato, S., Sato, K., Kameyama, M., Ogawa, A., Yoshimoto, T., Hatazawa, J., and Ito, M. (1992). Cerebral blood flow and oxygen metabolism in infants with hydrocephalus. *Child's Nervous System* 8: 118-123.
- Suda, K., Sato, K., Takeda, N., Miyazawa, T., and Arai, H. (1994). Early ventriculoperitoneal shunt effects on learning ability and synaptogenesis of the brain in congenitally hydrocephalic HTX rats. *Child's Nervous System* 10: 19-23.
- Tashiro, Y., and Drake, J. M. (1998). Reversibility of functionally injured neurotransmitter systems with shunt placement in hydrocephalic rats: Implications for intellectual impairment in hydrocephalus. *Journal of Neurosurgery* 88: 709-717.
- Tashiro, Y., Drake, J. M., Chakraborty, S., and Hattori, T. (1997). Functional injury of cholinergic, GABAergic and dopaminergic systems in the basal ganglia of adult rat with kaolin-induced hydrocephalus. *Brain Research* 770: 45-52.
- Thompson, M. G., Eisenberg, H. M., and Levin, H. S. (1982). Hydrocephalic infants: Developmental assessment and computed tomography. *Child's Brain* 9: 400-410.
- Thomson, N. M., Fletcher, J. M., Chapieski, L., Landry, S. H., Miner, M. E., and Bixby, J. (1991). Cognitive and motor abilities in preschool hydrocephalics. *Journal of Clinical and Experimental Neuropsychology* 13: 245-258.
- Torkelson, R. D., Leibrock, L. G., Gustavson, J. L., and Sundell, R. R. (1985). Neurological and neuropsychological effects of cerebral spinal fluid shunting in children with assumed arrested ("normal pressure") hydrocephalus. *Journal of Neurology, Neurosurgery and Psychiatry* 48: 799-806.
- Van der Knaap, M. S., Valk, J., Bakker, C. J., Schooneveld, M., Faber, J. A., Willemse, J., and Gooskens, R. H. (1991). Myelination as an expression of the functional maturity of the brain. *Developmental Medicine and Child Neurology* 33: 849-857.
- Villani, R., Tomei, G., Gaini, S. M., Grimaldi, N., Spagnoli, D., and Bello, L. (1995). Long-term outcome in aqueductal stenosis. *Child's Nervous System* 11: 180-185.
- Whittle, I. R., Johnston, I. H., and Besser, M. (1985). Intracranial pressure changes in arrested hydrocephalus. *Journal of Neurosurgery* 62: 77-82.

The Importance of a Neuropsychological Assessment



M. Alex Peterson, Ph.D.

Neuropsychology
Assessment Service

Children's Hospital
Oakland

Presentation Outline

- I) What is Neuropsychology?
- II) Hydrocephalus & the brain
- III) Neuropsychology of Hydrocephalus
- IV) Academic Issues
- V) Accommodations/Interventions

got?

What Are Neuropsychological Tests?

- object manipulation - verbal questions – memory – problem solving - observations Etc.
- Nationally Normed—compared to age matched peers
- Psychological Tests = Objective & Projective

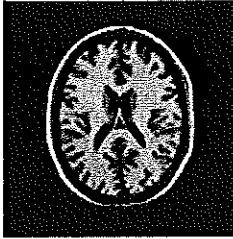
After the Testing...

- Data Scoring/Analysis
- Diagnosis?
- Feedback
- Recommendations
- Report
- Advocacy/Follow Up

Logistics....

- How to Find a Neuropsychologist
- Cross Checking
- Time Investment
- Insurance Matters...
- 'Out of Pocket' Costs

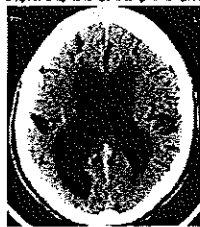
The Ventricles are....



Normal Brain

- Middle of the Brain
- Surrounded by white matter
- Why white matter is white
- What white matter does

Hydrocephalus can cause....



Hydrocephalic brain

- Increased Intra-ventricular pressure = expansion of ventricles + displacement of adjacent brain structures... most notably...white matter

common findings

- Impaired cerebral blood flow
- Changes in metabolism and neurotransmission
- Damage to white matter tracts
- stretching/thinning of corpus callosum
- Compression of the caudate Nucleus
- Cortical neurons *may* be damaged
- Severe cases=thinning of the cortex

III) Neuropsychology of Hydrocephalus

Before we begin ...

- Individual variability
- Overall there is no distinct 'cognitive profile'
- Heterogeneity of older studies

Moreover....

- cognitive deficits can be a consequence of the medical issue that precipitated the hydrocephalus (e.g. tumor, IVH)
- Wide variability
- study findings are not necessarily *predictive* of the individual

in General...

As a group patients with hydrocephalus have...

- Lower overall IQ scores
- Higher incidence of 'Learning difficulties' & mental retardation
- Lower academic performance... particularly in mathematics

Cocktail Party Syndrome

- Good expressive language skills
- Fluent Speech
- Poor receptive language
- Language is tangential and Irrelevant to the conversation
- Stereotypic phrases and vocabulary that are above ability level are common.

Problems with 'Social Cognition'

- Picking up on non-verbal communication
- Emotional and social reciprocity
- Social perspective taking
- Functioning in group situations
- detecting 'social cues' (e.g. Knowing when to stop talking)

Non-Verbal Learning Disability/NLD

- Deficits in visuo-spatial ability, Fine/gross motor skills, language/social pragmatics
- Strengths in expressive verbal skills, memory for facts/details and good word decoding skills
- Academic difficulties in math and conceptual subjects
- Thought to be functional manifestation of injury to white matter and/or right hemisphere

Other common issues...

- Poor physical coordination
- Difficulty completing timed tests
- Poor art skills
- Memory Retrieval problems 'tip of the tongue'
- Transition difficulties
- Misunderstood by teachers
- Emotional/self esteem difficulties

V) Accommodations & Interventions



Aka.. The 'go nuts' with clip art slide

Academic Support

- Individualized Education Plan
- Resource Specialist Support
- Speech and Language therapy
- Occupational Therapy
- Social Skills training (school or private)
- Teaching Strategies in the mainstream classroom
- Adaptive Physical Education
- Not being 'overly supportive'
- Teaching to child's individual strengths
- In-service on Hydrocephalus
- Assistive technology

In college...

- reduced but continued accommodations
- Extended time on tests
- Note taking
- Quiet test environment
- Specific department within college
- Realistic Course planning
- Modified curriculum
- Gradual transition to Self-advocacy
- Pda, computers & assistive devices

Job Accommodations

- American's with Disabilities Act
- Upfront with employer
- Careful selection of job & duties
- assistive devices
- Neuropsychological assessment for job planning purposes

The End!

